

*LSUHSC-S Renal Pathology Consultative Services*  
*Interesting Case*

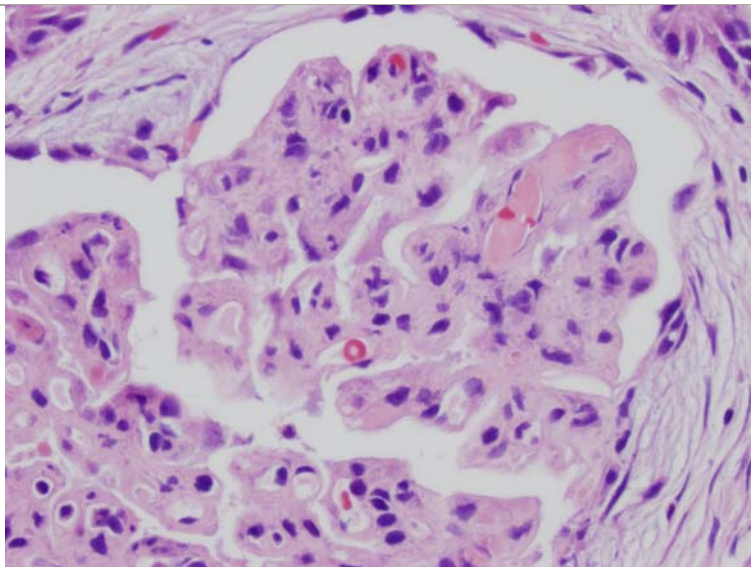
**Case Study #: 13**  
02/08/10 Questions

**By:** Stephen M. Bonsib, M.D.  
Xin Gu, M.D., Ph. D.  
Ami Bhalodia, M.D.

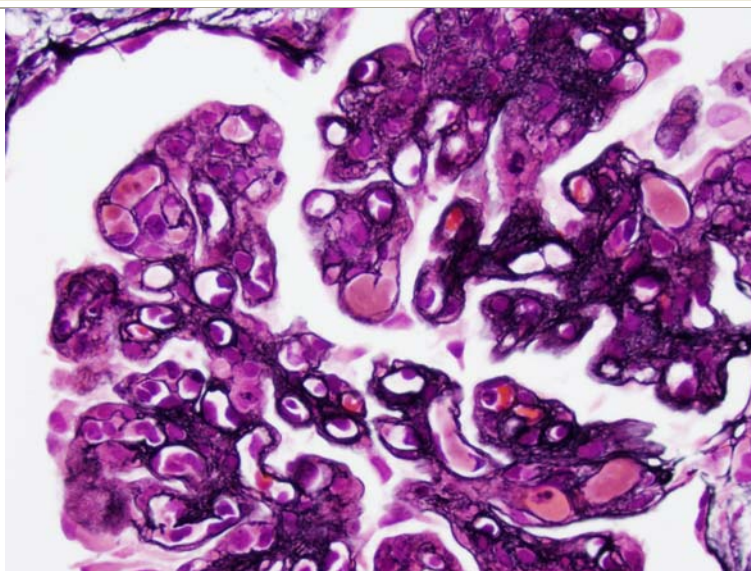
318-675-4557 phone  
318-675-4541 fax  
sbonsi@lsuhsc.edu  
xgu@lsuhsc.edu  
abhala@lsuhsc.edu

**Clinical History:** Patient is a 44 year old female that presented with proteinuria (10gms), low C3 and C4.

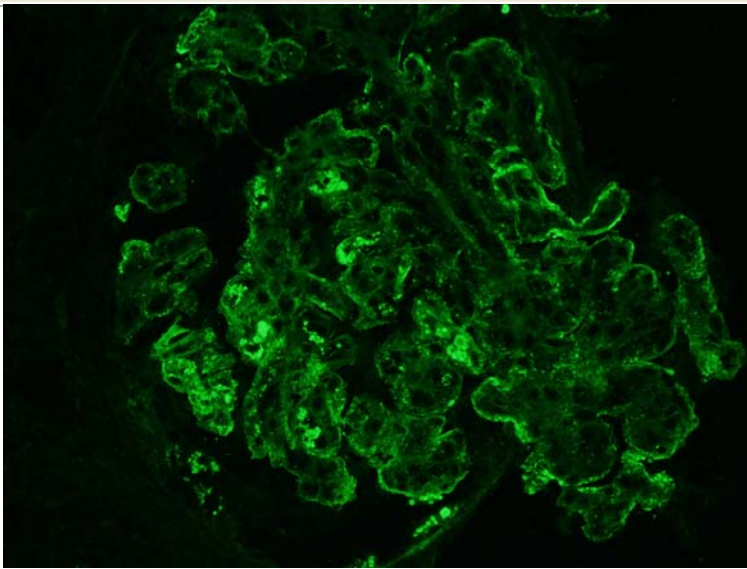
Case courtesy of Dr. Steven Turley, MD



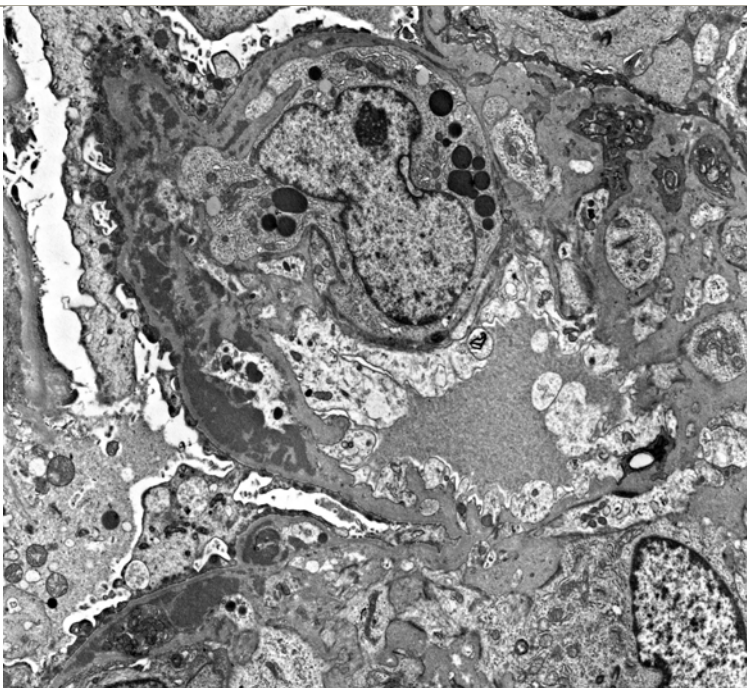
**Figure 1: H&E stain showing intraluminal thrombi**



**Figure 2: A Jones silver stain highlighting additional intraluminal thrombi**



**Figure 3: IF for IgG revealing diffuse coarse granularity in capillary loops and mesangial areas. In addition, several capillary loops contain thrombi.**



**Figure 4: EM of subendothelial deposits**

**Question:**

1. What additional clinical or laboratory information is required?
2. What is the differential diagnosis based on the LM findings?
3. What is the diagnosis based on the IF and EM findings?
4. What is the clinical course and prognosis for this disease?

**Answer:**

Answer to be provided via e-mail next week.